

High Pathologic Complete Response (pCR) in Her2-positive Breast cancer to Novel Non-anthracycline Neoadjuvant Chemotherapy

A.B. Zelnak¹, B. Leyland-Jones¹, S.G. Gabram¹, T.M. Styblo¹, M. Rizzo¹, W.C. Wood¹, J Srinivasiah², W. Jonas², F. Schnell², R.M. O'Regan¹

¹Winship Cancer Institute at Emory University School of Medicine, ²Georgia Center for Oncology Research and Education

Abstract

Background: The addition of trastuzumab to preoperative chemotherapy for Her2-positive breast cancers has been shown to increase pCR rates. The purpose of this study was to evaluate the efficacy of trastuzumab in combination with dose-dense nab-paclitaxel followed by weekly vinorelbine.

Methods: Patients with Stage I (>1.0 cm), II, or IIIA Her2-positive (defined as either immunohistochemical 3+ of fluorescence in situ hybridization-positive) breast cancer received nab-paclitaxel 260 mg/m² iv every 2 weeks for 4 cycles in combination followed by vinorelbine 25 mg/m² iv weekly with simultaneous trastuzumab (4 mg/kg loading dose then 2 mg/kg weekly) for 20 weeks. Tissue was collected at baseline, at optional midway biopsy, and post-therapy. Primary endpoint was pCR rate; secondary endpoints included response rate and toxicity. Cardiac evaluation was performed at baseline, after 4 cycles of nab-paclitaxel, after 12 weeks of vinorelbine and every 3 months thereafter.

Results: To date, 21 of 50 planned patients have been accrued (3/2008 to 12/2009). 11 patients are evaluable for primary endpoint. Median age was 50.5 years (38-64). Median tumor size was 3.7 cm (1.5-7cm). 4 of 11 (36.4%) were clinically node-positive at study entry. Patients were accrued from a university center (54.5%), county hospital (18.2%), and community sites (27.3%). 4 patients were African American (36.4%), 7 were Caucasian (63.6%). The regimen was well-tolerated: 2 patients experienced grade 3 neuropathy, 1 patient grade 3 neutropenia, 1 patient had trastuzumab held for asymptomatic decrease in left ventricular ejection fraction. Clinical complete response rate was 72.7%. Partial response rate was 27.3%. 7 of 11 patients (63.6%) had pCR.

Conclusions: The combination of preoperative trastuzumab with dose-dense nab-paclitaxel followed by vinorelbine was well-tolerated and resulted in a high rate of pCR in Her2-positive breast cancer.

Introduction

The human epidermal growth factor receptor 2 (Her-2) is overexpressed in 20 to 25% of invasive breast cancers.¹ Several randomized trials in the adjuvant setting have evaluated the addition of trastuzumab to chemotherapy, and have shown improved disease-free and overall survival.² In the neoadjuvant setting, trastuzumab in combination with chemotherapy has been shown to increase pathologic complete response (pCR) rate.³ pCR is often considered a surrogate marker of outcome after neoadjuvant therapy. This is based upon observation from several, large randomized clinical trials showing that achievement of a pCR predicted for a more favorable long-term outcome.⁴ Optimal combination of trastuzumab and chemotherapy in neoadjuvant setting has not been determined. Cardiac toxicity is decreased when combining trastuzumab with a non-anthracycline based regimen.⁵ Nab-paclitaxel is a unique albumin-bound formulation of paclitaxel that has shown improved response rate and time to progression compared to paclitaxel in the metastatic setting.⁶ This study evaluates the novel combination of trastuzumab with dose-dense nab-paclitaxel followed by weekly vinorelbine.

Methods

Primary Objective

- Pathologic complete response rate (pCR) in the breast and axilla at the time of surgery

Secondary Objectives

- Clinical response rate
- Safety profile
- Correlative studies (ER, PR, HER2/neu, EGFR) before and after treatment

Eligibility Criteria

- Histologically confirmed invasive breast cancer
- Her2/neu 3+ by IHC or positive by FISH
- Stage I-IIIa (T1c-T3, N0-2)
- Measurable disease by either breast imaging or physical exam
- ECOG performance status of 0 to 1
- Women who are pregnant or lactating are not eligible
- Prior chemotherapy, radiation therapy, or hormonal therapy for breast cancer for breast cancer is not allowed
- Age ≥18 years
- Adequate renal, hepatic, and hematologic function
- Left ventricular ejection fraction greater than 50% as measured by MUGA or echocardiogram
- Peripheral neuropathy above grade 1 is not allowed

Treatment Plan

- Patients received nab-paclitaxel 260 mg/m² iv over 30 minutes every 14 days for 4 cycles followed by vinorelbine 25 mg/m² iv weekly with simultaneous trastuzumab (4 mg/kg loading dose then 2 mg/kg weekly) for 20 weeks
- Tissue was collected at baseline, optional midway biopsy, and at the time of surgery

Results

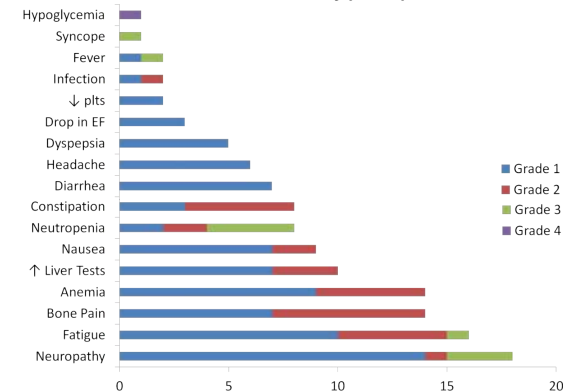
Patient Characteristics (n=21)

Median Age (range)	49.8 (34 - 64)
Median Tumor Size (range)	4.1 cm (1.5 - 7.0)
Race	
Caucasian	10 (47.6%)
African American	10 (47.6%)
Other	1 (4.8%)
Clinical Stage	
I	0 (0%)
II	17 (81.0%)
III	4 (19.0%)
Node Positive	12 (57.1%)
Histologic Grade	
I	2 (9.5%)
II	15 (71.5%)
III	4 (19.0%)
ER-positive	6 (28.6%)
PR-positive	5 (23.8%)
Menopausal Status	
Premenopausal	8 (38.1%)
Postmenopausal	13 (61.9%)
Accrual Site	
University Hospital	11 (52.4%)
County Hospital	4 (19.0%)
Community Sites	6 (28.6%)

Response (n=21)

Complete Response	16 (72.7%)
Partial Response	5 (27.3%)
Stable Disease	0 (0%)
pCR	11 (52.4%)

Toxicity (n=21)



Conclusions

- The combination of trastuzumab with dose-dense nab-paclitaxel is well tolerated. Main toxicities observed were fatigue and neuropathy. Two patients had trastuzumab held for asymptomatic drop in ejection fraction.
- pCR rate of 52.4% is higher than previously reported with non-anthracycline based chemotherapy in combination with trastuzumab.
- Additional evaluation of residual cancer burden planned.

References

- Slamon DJ: Proto-oncogenes and human cancers. N Engl J Med 317:955-7, 1987
- Romond EH, Perez EA, Bryant J, et al: Trastuzumab plus adjuvant chemotherapy for operable HER2-positive breast cancer. N Engl J Med 353:1673-84, 2005
- Buzdar AU, Ibrahim NK, Francis D, et al: Significantly higher pathologic complete remission rate after neoadjuvant therapy with trastuzumab, paclitaxel, and epirubicin chemotherapy: results of a randomized trial in human epidermal growth factor receptor 2-positive operable breast cancer. J Clin Oncol 23:3676-85, 2005
- Rastogi P, Anderson SJ, Bear HD, et al: Preoperative chemotherapy: updates of National Surgical Adjuvant Breast and Bowel Project Protocols B-18 and B-27. J Clin Oncol 26:778-85, 2008
- Slamon D et al: Phase III Randomized Trial Comparing Doxorubicin and Cyclophosphamide Followed by Docetaxel (AC-T) with Doxorubicin and Cyclophosphamide Followed by Docetaxel and Trastuzumab (AC-TH) with Docetaxel, Carboplatin and Trastuzumab (TCH) in Her2neu Positive Early Breast Cancer Patients: BCIRG 006 Study. San Antonio Breast Cancer Symposium 2009, abstract 62.
- Gradišar WJ, Tjulandin S, Davidson N, et al: Phase III trial of nanoparticle albumin-bound paclitaxel compared with polyethylated castor oil-based paclitaxel in women with breast cancer. J Clin Oncol 23:7794-803, 2005